



Lingual Osteoma in a Young Lady

Santhosh Kumar TN*

Department of Orthopaedics, Employee State Insurance Corporation, India

***Corresponding author:** Santhosh Kumar TN; Department of Orthopaedics, Employee State insurance Corporation, India, Email: santhosh01101985@gmail.com

Short Communication

Volume 9 Issue 2

Received Date: January 06, 2025

Published Date: April 18, 2025

DOI: 10.23880/jobd-16000287

Short Communication

I was sitting in my clinic, a quite Sunday, a young lady knocked my door with her mother. She was anxious and willing to say something. As conversation progressed her main complaint was feeling something in the mouth. Whenever her tongue lick the hard palate she feels the mass in her tongue. As I further examined her and done the literature review I suspected lingual Osteoma.. All the lingual Osteoma reported so far are benign and needs further follow up for contributing for distant ontogenesis in the body.

Benign osteogenic tumor made of mature benign bony tissue is called osteoma, predominantly found in the mandible, Maxilla and sinuses of the head and neck region bones [1,2]. Mouserrat M reported the first case of Lingual osteoma there after only 100 cases have been reported world wide.

Lingual Osteoma occurs less in man rather than women (1.00-3.25) [2], It is observed mainly in third and fourth decades of life with 5 to 73 years of age range [2,3]. Nausea (3.4%), evoked gagging (5.1%), dysphagia (6.9%), sensation in the throat (25.8%) are the common presenting symptoms although most of the patients are asymptomatic [4-7]. Posterior third of the dorsal tongue near the foramen cecum is the origin of the most lesions which are pedunculated, unilateral measuring 0.5- 2 cm in diameter. Large lesions causes difficulty in breathing due to upper airway obstruction. We can see the osteoma in other parts of the tongue [8].

Haversian -like canals, which was surrounded by a thin fibrous capsule covered by stratified squamous epithelium are the features of osteoma on histological examination [4] (Figure 1&2).

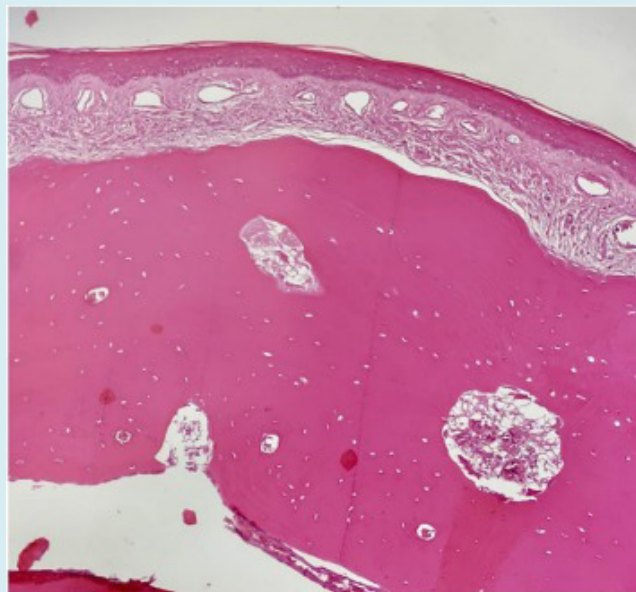


Figure 1: Stratified squamous epithelium of mature bone trabecular with fibrous stroma (Credit-Science Direct).

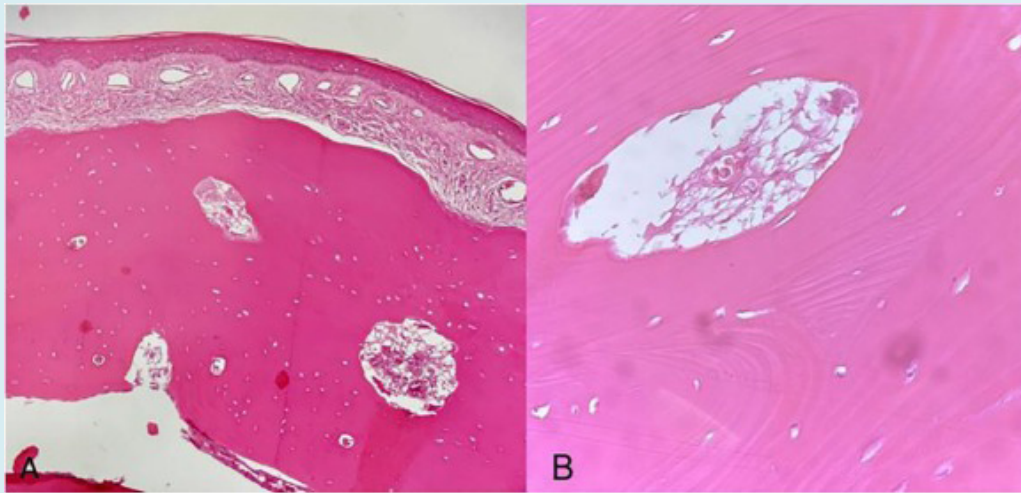


Figure 2: Stratified squamous epithelium of mature bone trabecular with fibrous stroma A B (Credit-Science Direct).

Three theories about origin of lingual osteoma was proposed. Monserrat suggested 'branchial arch persistence' or 'developmental malformation theory' [5].

Branchial Arch Persistence Theory

The anterior two – thirds of the tongue originate from the first and the posterior third of the branchial arch. Later they fuses at the region of foramen cecum . From branchial arch bony structures originates with mesenchymal pluripotential cells through endotracheal ossification that may lead to formation of lingual osteoma but it fails to explain more lesions in women rather than men [7,9].

Lingual Thyroid Remnant Ossification Theory

The thyroid gland after originating from foramen cecum descends to neck. The remnant undescended thyroid tissue ossifies to give rise to lingual osteoma. This theory supports more prevalence of lingual osteoma in female [7,10-13]

Posttraumatic Reaction Theory

Post -traumatic reaction theory suggests that lesions are reactive with post -traumatic ossification, but this type of ossification lacks the haversian systems found in the lingual osteoma [7,8], Lingual osteoma are treated with surgical excision. Intra oral osteoma may reoccur but lingual osteoma recurrence had not been reported. There is no malignant transformation.

References

- Jalil SA, Mohamad I, Ahmad MA, Yusof Z (2016) Lingual Osteoma: A Rare Cause of Lump in the Throat. International Medical Journal 23(5): 592-593.
- Liu SC, Su WF, Nieh S, Lin DS, Chu YH (2010) Lingual osteoma. J Med Sci 30(3): 97-99.
- Sohrabi C, Mathew G, Maria N, Kerwan A, Franchi T, et al. (2023) The SCARE 2023 guideline: updating consensus Surgical CAse REport (SCARE) guidelines. Int J Surg Lond Engl 109(5): 1136-1140.
- Liu JY, Tan KK (2011) Lingual osteoma: case report and Singapore literature review. Med J 52(10): e198-200.
- Monserrat M (1913) Osteoma de langue. Bull Soc Anat 88: 282-283.
- Benamer MH, Elmangoush AM (2007) Lingual osseous choristoma case report and review of the literature. Libyan Journal of Medicine 2(1): 46-48.
- Sun HA, Lee WT, Hsu HJ (2022) Lingual osteoma —a case report and literature review. Ear, Nose & Throat Journal 101(10): 647-649.
- Supiyaphun P, Sampatanakul P, Kerekhanjanarong V, Chawakitchareon P, Sastarasadhith V (1998) Lingual osseous choristoma: a study of eight cases and review of the literature. Ear, nose & throat journal 77(4): 316-325.
- Vered M, Lustig JP, Buchner A (1998) Lingual osteoma: a debatable entity. Journal of Oral and Maxillofacial Surgery 56(1): 9-13.
- Jahnke V, Daly JF (1968) Osteoma of the tongue. The Journal of Laryngology & Otology 82(3): 273-275.

11. Adhikari BR, Sato J, Morikawa T, Obara -Itoh J, Utsunomiya M, et al. (2016) Osseous choristoma of the tongue: two case reports. *Journal of Medical Case Reports* 10: 1-4.
12. Long DE, Koutnik AW (1991) Recurrent intraoral osseous choristoma: report of a case. *Oral surgery, oral medicine, oral pathology* 72(3): 337-339.
13. Dalkiz M, Yurdakul RH, Pakdemirli E, Beydemir B (2001) Recurrent osseous choristoma of the masseter muscle: case report. *Journal of oral and maxillofacial surgery* 59(7): 836-839.