



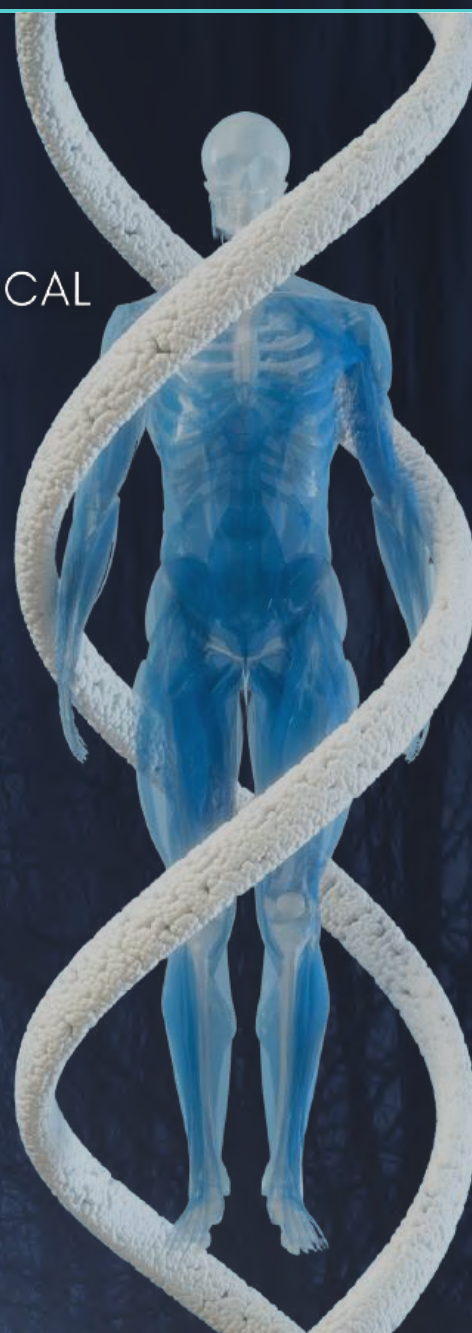MEDWIN PUBLISHERS
Committed to Create Value for Researchers

JOURNAL OF HUMAN ANATOMY (JHUA)

ISSN: 2578-5079

EXPLORING THE ANATOMICAL AND CLINICAL
PERSPECTIVES OF THE VERTEBRA
PROMINENS (C7)

Dr. Monika Lalit, Dr. Sanjay Piplani, Dr.
Anupama Mahajan and Niharika Piplani



Medwin Publishers

+1-248-247-6042



info@medwinpublishers.org



28475 Witherspoon dr, Novi, MI-
48377, United States

Exploring the Anatomical and Clinical Perspectives of the Vertebra Prominens (C7)

Lalit M^{1*}, Piplani S², Mahajan A¹ and Piplani N³

¹Professor, Department of Anatomy, SGRDIMSAR, India

²Professor, Department of Pathology, SGRDIMSAR, India

¹Director Principal Cum Professor, Department of Anatomy, SGRDIMSAR, India

³Third Prof Part 1 MBBS Student, SGRDIMSAR, India

***Corresponding author:** Dr. Monika Lalit, MBBS, MS, PGDMCH, MNAMS, ACME, Fellow PAPC, Department of Anatomy, Sri Guru Ram Das Institute of Medical Sciences and Research, India, Tel: 09814325454; Email: monika.lalit@yahoo.com

eBook

Received Date: December 05, 2024

Published Date: January 20, 2025

Published by



MEDWIN PUBLISHERS

Committed to Create Value for Researchers

Table of Contents

Title	Page No
Chapter 1: Introduction: Background and Significance of Vertebra Prominens in Anatomy and Clinical Practice	1
Chapter 2: Aims and Objectives: Purpose of the study/Chapter and Specific objectives	2
Chapter 3: Ontogeny: Development of Vertebra Prominens	3
Chapter 4: Phylogeny: Evolutionary Perspective of Vertebra Prominens	4
Chapter 5: Anatomy: Anatomical Features of Vertebra Prominens	5
Chapter 6: Muscles and Ligaments: Muscles and Ligaments associated with Vertebra Prominens	6
Chapter 7: Variations: Anatomical variations of Vertebra Prominens clinical implications	7
Chapter 8: Review of Literature: Overview of Existing Research and Identification of Gaps in Current Literature	8
Chapter 9: Materials and Methods: Data Collection, Analytical Techniques and Methodological Approach	9
Chapter 10: Discussion: Interpretation of Findings and their Clinical Relevance	13
Chapter 11: Advanced Imaging Techniques in Evaluating Vertebra Prominence (C7): The Role of MRI and CT Scans in Clinical Perspective	15
Chapter 12: Conclusion: Summary of Findings and Directions for Future Research	16
Acknowledgement	17
References	17

Abstract

The vertebra prominens is unique for its palpable prominence at the dorsum of the neck that serves as a key landmark in both clinical examinations and surgical procedures. Anatomical and morphometric aspects of the vertebra prominens also play a very important role in degenerative, traumatic and neoplastic diseases of the cervical spine and also as a reference point in surgery. This e-book “Exploring the Anatomical and Clinical Perspectives of the Vertebra Prominens” provides an in-depth analysis of its morphological and morphometric components. Dry bone specimens were utilized to measure vertebra prominens’s key parameters, including body dimensions, pedicle, laminae, spinous process, and the diameters of the foramen transversarium and vertebral foramen. Morphological variations of vertebra prominens include differences in the shape, size and presence of the foramen transversarium, bifid or elongated spinous processes, and cervical ribs. Studies on its morphometry highlight variability in the body, foramen transversarium and pedicle dimensions, with implications for conditions such as thoracic outlet syndrome and cervical spine trauma. Ethnic variations have also been reported in these dimensions. Its transitional design reflects the evolutionary balance between stability and mobility in the cervical-thoracic junction. The knowledge of such variations is critical for planning surgical interventions, understanding neurovascular compression syndromes, and enhancing diagnostic precision in cervical spine imaging. These parameters of vertebra prominens(C7) with combined effects of axial computed tomography, provide valuable insights in correct estimation of spinal deformities and are of interest from anatomical, anthropological and medicolegal point of view.

Keywords: Lamina; Morphometry; Seventh Cervical Vertebra; Spine; Vertebra Prominens

Abbreviations

IAF: Inferior Articular Facet; SAF: Superior Articular Facet; FT: Foramen Transversarium; VBL: Vertebral Body Length; VBSW: Vertebral Body Superior Width; VBIW: Vertebral Body Inferior Width; VBAH: Vertebral Body Anterior Height; VBPH: Vertebral Body Posterior Height.

Chapter 1: Introduction: Background and Significance of Vertebra Prominens in Anatomy and Clinical Practice

Among the cervical vertebrae, the seventh cervical vertebra (C7) known as the vertebra prominens is responsible for the palpable prominence at the dorsum of the neck. This anatomical feature serves as a key landmark in both clinical examinations and surgical procedures. The body of C7 sometimes bears a costal pit near its caudal border for the head of the first rib, which may present as a well-developed cervical rib [1]. The vertebra prominens is unique not only for its palpable prominence but also for its potential anatomical variations holding significant clinical interest for clinicians, including radiologists, neurologists, and orthopaedic surgeons. For instance, anatomical variations in the C7 spinous process, such as duplication, have clinical implications, as these anomalies may be associated with other congenital malformations [2]. Apophysomegaly of the C7 is linked to conditions like acroparesthesia and amyotrophy of the hand, while Clay-Shoveller's fracture of the C7 spinous process is caused by direct trauma or forceful muscular action [3,4]. X-ray irradiation of C7 is even employed in the treatment of psoriasis [5]. Given the vital role of the cervical vertebrae in maintaining spinal curvature and facilitating neck movement, injuries to this region often require immediate medical intervention, especially in polytrauma cases. Any deviation in the morphology or morphometric characteristics of the vertebra prominens can have serious implications for vascular structures, such as the vertebral artery, particularly in cases of narrowing of the foramen transversarium, which can lead to neurological

complications [6]. Osteophyte formation at the superior border of vertebra prominens is also prevalent, contributing to conditions like radiculopathy due to spinal cord or nerve root compression [7,8]. The surgeons and forensic experts should be aware of complications in evaluating a case with severe trauma of cervical spine [9]. Given its role in cervical stability and mobility, the vertebra prominens is of paramount importance in the assessment and management of cervical spine injuries, especially in patients with pre-existing conditions such as ankylosing spondylitis. Thus, understanding the anatomy and potential anomalies of the vertebra prominens is essential for various medical specialties, highlighting the need for comprehensive preoperative evaluations and radiological assessments.

Summary

The vertebra prominens, or C7 vertebra, is distinguished by its long, palpable spinous process and serves as a vital anatomical landmark in the cervical spine. It marks the transition between the cervical and thoracic regions, contributing significantly to spinal stability and mobility. Morphometric analysis of its components, such as the body, pedicles, foramen transversarium, vertebral foramen, and spinous process, highlights its anatomical and clinical significance. Its unique anatomy is pivotal in clinical scenarios such as neurovascular surgeries, spinal stabilization, and diagnostic imaging.

Chapter 2: Aims and Objectives: Purpose and Specific Objectives

This chapter aims to explore the anatomical, clinical, and surgical significance of the cervical vertebrae, with a particular focus on the seventh cervical vertebra. The specific objectives are:

1. To study the anatomical features of the seventh cervical vertebra (vertebra prominens) and its common variations.
2. To explore the developmental (ontogenic) aspects of the vertebra including precartilage, chondrification, and ossification.
3. To identify and discuss variations in the seventh cervical vertebra and their clinical implications.
4. To assess the clinical relevance of variations in the cervical vertebrae, especially the seventh vertebra, for

different medical specialties.

5. To summarize historical and contemporary research related to cervical vertebrae anatomy, variations, and associated clinical issues.

Summary

The study aims to systematically measure and analyze the dimensions of the vertebra prominens, focusing on its body, pedicles, spinous process, foramen transversarium, and vertebral foramen. These findings aim to improve understanding of its anatomical variations and their relevance in clinical and surgical contexts.

Chapter 3: Ontogeny: Development of Vertebra Prominens

The development of vertebrae occurs in three stages: the precartilage stage, chondrification stage and classification stage [10].

1. Precartilage Stage: Cells of the sclerotome migrate in three directions:

- **Ventromedially:** Cells surround the notochord and form the vertebral body.
- **Dorsally:** Cells form the neural arch.
- **Ventrolaterally:** Cells form the costal process.

2. Chondrification Stage: The chondrification stage of the vertebral prominence is a critical phase in vertebral development where mesenchymal tissue begins to differentiate into cartilage. It further lays the groundwork for the ossification of the spinous process, which later becomes the prominent bony projection at the back of the neck (most notably in the 7th cervical vertebra). Chondrification of the posterior arch begins at the pedicle.

3. Ossification Stage: The cartilaginous arch ossifies. The costal process ossifies around the sixth month and fuses with the body and transverse process by the fifth or sixth year. Complete absence of both cartilaginous and bony components of the posterior elements indicates an early developmental fault. Occasionally, the costal processes remain separate, developing as cervical ribs. During embryogenesis, the neural arches extend laterally from the centrum and also form a complete or incomplete foramen transversarium. Developmental defects at this stage may lead to an absence of posterior elements.

Summary

The vertebra prominens develops from somites in the embryo, with distinct ossification centers for the body, neural arches, and spinous process. Its formation and fusion occur during early childhood, contributing to the cervical spine's structural integrity and functional role in neck mobility and load transmission.

Chapter 4: Phylogeny: Evolutionary Perspective of Vertebra Prominens

The phylogeny of vertebral prominence, specifically the seventh cervical vertebra (C7), reveals its evolutionary significance in vertebrates. In early vertebrates like fish and amphibians, the cervical vertebrae were less specialized, as their primary mode of movement did not require significant neck flexibility. As tetrapods evolved and moved onto land, there was a need for greater neck mobility to aid in head movement, feeding, and sensory perception. In reptiles and early mammals, the cervical spine began to show differentiation, with C7 becoming more prominent to support the transition to more complex locomotion. The vertebral prominence of C7 in humans is particularly notable because of its structural role in supporting head movement and posture. In bipedal species, C7 serves as a critical junction, providing support for both the neck and upper thoracic regions while maintaining the flexibility necessary for a wide range of head movements. Its prominence, felt at the base of the neck, became more pronounced in hominids, as an upright posture increased the mechanical demands

on the cervical spine for balance and weight distribution. This evolutionary development reflects the transition from quadrupedal to bipedal locomotion, emphasizing C7's role in enhancing spinal stability and facilitating human upright posture. In evolutionary terms, the vertebra prominens marks the transition between the mobile cervical spine and the more stable thoracic region, making it susceptible to both mobility-related injuries and degenerative changes.

Summary

Evolutionarily, the vertebra prominens demonstrates adaptations associated with bipedal locomotion. In humans, it exhibits robust features to support an upright posture, unlike quadrupeds, where cervical vertebrae are optimized for head movement. Its transitional design reflects the evolutionary balance between stability and mobility in the cervical-thoracic junction.

Chapter 5: Anatomy: Anatomical Features of Vertebra Prominens

The seventh cervical vertebra is characterized by its long, powerful, non-bifurcated spinous process, which is typically the first palpable structure when examining the spine from above. They are also characterized by the presence of foramina in the transverse process known as foramina transversarium [10-14].

1. Body: A costal pit (fovea costalis) may be present on the lower margin of the lateral surface of the body, for articulation with the head of first rib. The seventh cervical vertebra can resemble the first thoracic vertebra if it bears a pair of ribs or may take on the characteristics of the sixth cervical vertebra when the first thoracic ribs are rudimentary and reduced to the condition of cervical ribs. According to Wood Jones, there is a definite correlation between the occurrence of ribs on the seventh vertebra or reduction of ribs on eighth vertebra.

2. Vertebral Arch: Together, the pedicles and laminae the pedicles and laminae collectively form the vertebral arch (neural arch) that protects the spinal cord.

- **Pedicles:** Extends from the posterior side of the vertebral body and forms the lateral boundaries of the vertebral foramen and support the posterior elements of the vertebra.
- **Laminae:** Project posteriorly from the pedicles and converge at the midline to complete the vertebral arch.

3. Articular Processes of the Vertebra Prominens (C7): The articular processes of the vertebra prominens (C7) play a crucial role in its articulation with adjacent vertebrae and contribute to the overall stability and mobility of the cervical spine. These particular processes are essential for facilitating controlled motion and maintaining the alignment of the cervical vertebrae, especially the prominent C7.

- **Superior Articular Facets:** These extend upwards from the C7 vertebra and articulate with the inferior articular processes of the 6th cervical vertebra (C6). They are located posterior to the pedicles and contribute to the facet joints of the cervical region.
- **Inferior Articular Facets:** These project downward from the C7 vertebra and connect with the superior articular processes of the 1st thoracic vertebra (T1). They are positioned below the pedicles and participate in the facet joints, aiding in the smooth movement between adjacent vertebrae.

4. Transverse Process: The transverse processes are massive and only slightly grooved having following components.

- **Dorsal Bar:** The dorsal bar is stout with a large, prominent tubercle and provides support for muscle attachments
- **Ventral Bar:** The ventral bar is slight, with an absent or faintly marked tubercle.
- **Costal Process:** It is separate and independent element in the embryo also called as processus costarium usually more feebly developed than the posterior part, but is sometimes encountered as movable, so-called cervical rib where its length may vary greatly. It is grooved superiorly for anterior ramus of the cervical nerve. while both types of bars are involved in the vertebral development process, costal bars are specifically related to rib formation, whereas ventral bars are involved in the development of the vertebral body and anterior structures.

5. Foramen Transversarium: The vertebral artery and vein do not traverse the foramen transversarium of this vertebra. However, an accessory vertebral vein may pass through it. The foramen may also be absent or very small and is sometimes subdivided.

6. Vertebral Canal: It is formed by the vertebral body anteriorly, the pedicles laterally, and the laminae posteriorly. In C7, the vertebral canal is relatively smaller compared to other cervical vertebrae and provides a passage for the spinal cord and nerve roots.

7. Spinous Process: The spinous process is long and powerful, never bifurcated but ends in a broad tubercle, projecting under the skin for the attachment of ligament nuchae.

Summary

Vertebra Prominens exhibits unique anatomical features such as body, a prominent, typically non-bifid spinous process, robust transverse processes, and a variable foramen transversarium, which may or may not transmit the vertebral artery. These characteristics contribute to its role as a structural and functional bridge between cervical and thoracic vertebrae.

Chapter 6: Muscles and Ligaments: Muscles and Ligaments Associated with Vertebra Prominens

The vertebra prominens, which is the 7th cervical vertebra (C7), is distinctive for having a prominent spinous process that is easily palpable at the base of the neck. This vertebra serves as a key point of attachment for muscles and ligaments [13,14]. The prominent spinous process of C7 serves as a key anatomical reference point, particularly for muscles and ligament attachments involved in neck and upper back movements.

1. Muscle Attachments

- **Trapezius:** The superficial part of the trapezius muscle attaches to the spinous process of C7, contributing to movements of the scapula and upper limb.
- **Rhomboid Minor:** This muscle, involved in retracting the scapula, also attaches to the C7 spinous process.
- **Semispinalis Capitis:** Part of the deep back muscles, it attaches to C7 and plays a role in head and neck extension.
- **Multifidus and Spinalis:** These deep muscles of the back also attach to C7 and are important in stabilizing and extending the spine.

2. Ligament Attachments

- **Nuchal Ligament:** This thick, fibroelastic ligament runs from the occipital bone down to the spinous process of C7, providing support and limiting excessive flexion of the neck.
- **Supraspinous Ligament:** Extends from the spinous process of C7 down the length of the vertebral column, helping stabilize the spine.
- C7's prominent spinous process makes it a key reference point for anatomical orientation, particularly for the attachment of muscles and ligaments involved in neck and upper back movements.

Summary

Vertebra Prominens serves as an anchor point for muscles like the trapezius, rhomboids, and scalene, which facilitate head and neck movements, and for ligaments like the ligamentum nuchae and supraspinous ligament, which provide stability and limit excessive motion.

Chapter 7: Variations: Anatomical Variations of Vertebra Prominens Clinical Implications

Variations in the anatomy of the cervical vertebrae are common and can have significant clinical implications. Some key variations in the seventh cervical vertebra include:

1. Body

- Fusion between the sixth and seventh cervical vertebrae or between the seventh cervical and first thoracic vertebrae [15].
- There may also be incomplete fusion of bodies of 6th and 7th cervical vertebrae where a cleft is visible [15].
- Presence of osteophytes and are often better developed on the superior border of C7 [7].
- Tortuous vertebral arteries may cross the vertebral body, leading to erosion or clinical symptoms [16-18].

2. Pedicle and Lamina

- Erosions of the pedicles may be caused by an elongated and tortuous vertebral artery [17].
- There may be variations in the ossification pattern of the lamina in C7, which can result in anomalies like spina bifida occulta (incomplete closure of the lamina) or hypertrophied or sclerotic lamina due to degenerative conditions or excessive mechanical load [13,17].

3. Articular Facets

- Variations in the angle of inclination of the articular facets may be significant for clinical diagnoses [19].
- Hypertrophied articular facets or failure of fusion (cervical spina bifida) may compromise stability [8].
- Articular process on right side is irregular and fibrotic with osteophytes on its border indicating arthritis [6].

4. Transverse Process

- The transverse process may be bifid or replaced by a cervical rib
- The cervical ribs associated with C7 appear in variety of forms:
- It may be well developed cervical rib.
- There may be fully formed or mere enlargements of

costal processes.

- There may be complete pairs of ribs which may articulate with sternum.
- There may be rudimentary, appearing as a fibrous band that joins the usual first thoracic rib or first rib cartilage.
- It may also be associated with transverse megaapophysiomegaly with acroparesthalgia and amyotrophy of hand [3,20].

5. Foramen Transversarium

- C7 shows a predominance of type-4 and type-5 foramina transversaria, which are elliptical with an oblique orientation (right to left) or (left to right).
- Osteophyte impingement can also be seen on FT.
- Accessory FT or absent FT may be seen in the same vertebra may be if the costal process of seventh on left side is not connected laterally with the transverse process [6]. Bilateral accessory foramina are exhibited by V1 and V2 vertebrae Prominens. Unilateral accessory foramina on the left side are exhibited by V3 and V4 vertebrae Prominens.

6. Vertebral Canal: Narrowing of the vertebral canal due to osteophyte encroachment, hypertrophied articular facets or disc herniation [8].

7. Spinous Process:

- There may be duplicated spinous process [2].
- There may be dislocation and fracture of spinous process [21,22]

Summary

Morphological variations of vertebra prominens include differences in the size and presence of the foramen transversarium, bifid or elongated spinous processes, and cervical ribs. These anomalies can lead to clinical conditions like neurovascular compression, impacting diagnostic and surgical approaches.

Chapter 8: Review of Literature: Overview of Existing Research and Identification of Gaps in Current Literature

Tracing the pathways followed by masters in the field allows us to form a modern conception of scientific subjects. Reviewing history, we encounter numerous contributions by eminent medical personalities.

- **Das and Suri:** Reported a case of duplicated spinous processes in the seventh cervical vertebra, describing the anatomical details of this anomaly and presenting its radiological image. They noted that such anomalies might be associated with other congenital conditions [2].
- **Delbarre and Ramadier:** Examined apophysomegaly in seventh cervical vertebra, correlating this condition with acroparesthesia and amyotrophy of the hand [3].
- **Nathan:** Examined osteophyte formation in various conditions, shedding light on their causes, development, and clinical significance, with a detailed description of osteophytes in different spinal regions [7].
- **Maresova:** Explored the use of X-ray irradiation of the seventh cervical vertebra in the treatment of psoriasis, contributing to the understanding of medical imaging's role in therapeutic interventions [5].
- **Nikitin:** Reported on cases of dislocation of the seventh cervical vertebra, contributing to the understanding of vertebral dislocation and its clinical implications [22].
- **Borejko:** Provided an account of fractures involving the spinous process of the seventh cervical vertebra, adding to the clinical understanding of trauma to this region [21].
- **Anderson:** Measured the vertebral bodies to determine their relationships across various regions of the spine. He recorded the mean transverse and anteroposterior diameters of the vertebral bodies, along with the anterior and posterior vertical diameters, presenting these measurements in a tabulated form [23].
- **Cyriax:** Conducted a comprehensive study involving normal human vertebrae taken from 36 articulated and disarticulated skeletons, 9 dry preparations of vertebrae affected by war injuries, and approximately 600 loose vertebrae. A total of 1,482 bones were examined, and several metrical features were analyzed. This research laid the foundation for anatomical and anthropological studies, the interpretation of radiographs, the accurate estimation of spinal deformities, and served medicolegal purposes [24].
- **Willis:** Studied a series of 1,400 skeletons and categorized vertebral variations into three distinct groups based on phylogenetic, developmental, and acquired factors, providing a comprehensive classification system [25].
- **Cave:** Documented one of the earliest English examples of a bilateral cervical rib, specifically found in the articulated skeleton of Mary Bateman. The bilateral manifestation of the seventh cervical rib in this specimen is now preserved at the University of Leeds, making it a unique addition to the gallery of malefactors [26].
- **Wood-Jones:** Recorded facts regarding the condition of the cervical vertebrae in Australian natives. He compared European cervical vertebrae with Australian vertebrae and assessed the degree of Australian features in various other races [27].
- **Hinck et al.:** Explored the use of plain radiographic measurements in the diagnosis of intraspinal lesions. They recognized that tumors could enlarge the spinal canal by eroding vertebral structures. The sagittal diameter was measured from the middle of the posterior surface of the vertebral body to the ventral line of the cortex at the junction of the spinous process and lamina. [28].
- **Gilad and Nissan:** Presented a set of anthropometric measurements derived from radiographs of healthy male subjects. Their data provided a basis for anatomical, biomechanical, and ergonomic applications, including statistical analysis of vertebral dimensions in relation to height, weight, and age [29].
- **Fujiwara et al.:** Studied the prognosis of surgery for cervical compression myelopathy. They demonstrated that the severity of spinal cord pathology correlated with the degree of neurological impairment, and that surgical outcomes were related to the transverse area and anteroposterior compression ratio of the spinal cord [30].
- **Hyypa et al.:** Demonstrated the erosion of pedicles and vertebral bodies caused by the tortuous vertebral artery. These changes were visible on plain radiographs and confirmed through angiography of the aortic arch. They documented symptoms associated with this vertebral artery anomaly [31].

Summary

Existing research emphasizes the clinical importance of C7's anatomical features, particularly its role in imaging and as a reference point in surgery. Studies on its morphometry highlight variability in foramen transversarium and pedicle dimensions, with implications for conditions such as thoracic outlet syndrome and cervical spine trauma.

Chapter 9: Materials and Methods: Data Collection, Analytical Techniques and Methodological Approach

This section captures the observations, key measurements and processes involved in the study while maintaining a structured format.

Tools

Linear dimensions (length, breadth, and height) were measured using a vernier caliper with a least count of 0.02 mm, and data was recorded in a computer spreadsheet.

Samples

A total of sixty dry human adult seventh cervical vertebrae (C7) were analyzed.

Measurements

Surface dimensions and morphological features were assessed, focussing on various aspects of vertebra prominens (C7).

Morphological Features of Vertebra Prominens (C7)

- **Shape of superior articular facet (SAF):** Observed as Oval antero-posterior, Oval transverse, Circular, Irregular and crescentic.
- **Shape of inferior articular facet (IAF):** Observed as Oval antero-posterior, Oval transverse, Circular, Irregular and crescentic.
- **Shape of foramen transversarium :** Observed as round, elliptical, or with various oblique diameters which depends upon direction of the main diameter like elliptical with main diameter oblique (from right to left) or (from left to right).
- **Accessory foramen transversarium (FT):** observed as a Single, double or Triple FT of very small dimension. Absence of FT on one side or both the sides was also noted. There may be osteophyte encroachment within in the FT.
- **Shape of vertebral foramen:** Observed as Heart shaped, Oval, Circular and U-shape (Figures 1,2).

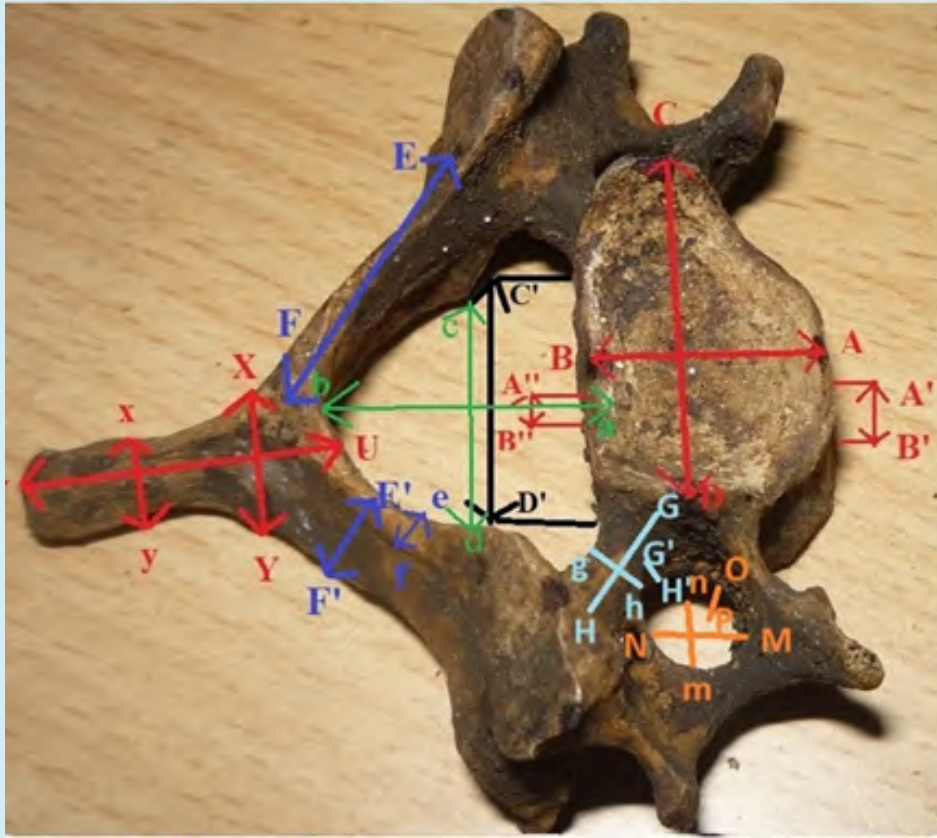


Figure 1: (For Chapter 9) Superior View of Vertebra Prominens Showing. The Dimensions of Vertebral Body, Pedicle, Lamina, Foramen transversarium, Vertebral Foramen and Spine.

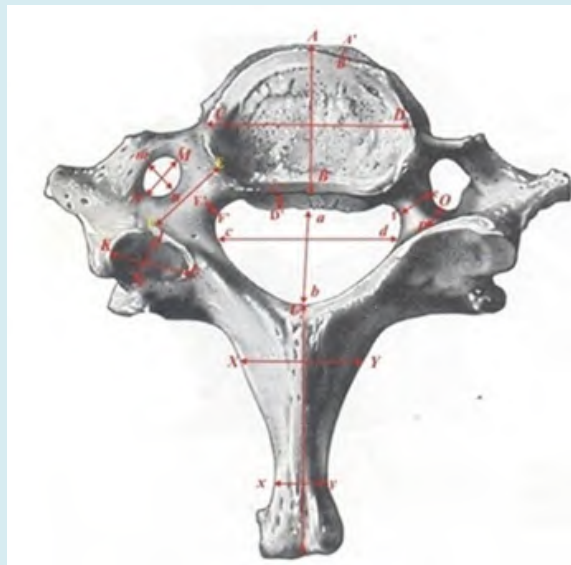


Figure 2: (For Chapter 9) Superior View of Vertebra Prominens Showing. The Dimensions Of Vertebral Body, Pedicle, Superior Articular facets, Foramen transversarium, Vertebral Foramen and Spine.

Morphometric Measurements of Vertebra Prominens (C7)

- Vertebral Body [29,32,33]:
- **Vertebral Body Length (VBL):** It is the greatest anteroposterior diameter of the centrum of the body in sagittal plane, measured as $AB = VBL$.
- **Vertebral Body Superior Width (VBSW):** it is the greatest transverse diameter of the centrum of vertebral body Measured as $CD = VBSW$.
- **Vertebral Body Inferior Width (VBIW):** The diameter was measured as the transverse width of the base of inferior aspect of vertebral body measured as $C'D' = VBIW$.
- **Vertebral Body Anterior Height (VBAH):** It is the maximum vertebral body height on the superoanterior and inferoanterior point on the vertebral body measured as $A'B' = VBAH$.
- **Vertebral Body Posterior Height (VBPH):** It is the maximum vertebral body posterior height on the most superoposterior point and on most inferoposterior point on the vertebral body measured as $A''B'' = VBPH$.

Pedicle

- **Pedicle Length (PL):** Length of the pedicle was measured from anterior most point of the pedicle axis to the posterior point of pedicle axis projection measured as $GH = PL$.
- **Pedicle Height (PH):** Height of the pedicle is measured from its superior surface to inferior surface within the foramen transversarium measured as $G'H' = PH$.

- **Pedicle Width (PW):** It was taken from internal surface of pedicle to its external surface at the level of transverse foramen measured as $gh = PW$ [34,35].

Laminae

- **Lamina Height (LH):** It is the distance between the superior and inferior borders on the lamina and marked as $E'F' = LH$ [32,33,36].
- **Lamina Length (LL):** It is the distance between the spinous process and the lateral border of the superior articular process on the lamina and marked as $EF = LL$.
- **Lamina Width (LW):** It is the maximum transverse width of the lamina and marked as $ef = LW$.

Superior Articular Facet (SAF)

- **Length (SAFL):** Length of superior articular facet is the greatest anteroposterior diameter of superior facet measured as $IJ = SAFL$.
- **Width (SAFW):** Width of superior articular facet is the greatest transverse diameter of superior facet measured as $KL = SAFW$.

Inferior Articular Facet (IAF)

- **Length (IAFL):** Inferior articular facet length is the greatest anteroposterior diameter of inferior facet measured as $ij = IAFL$ [32,36] (Figure 3).
- **Width (IAFW):** Inferior articular facet width is the maximum transverse diameter of inferior facet measured as $kl = IAFW$.

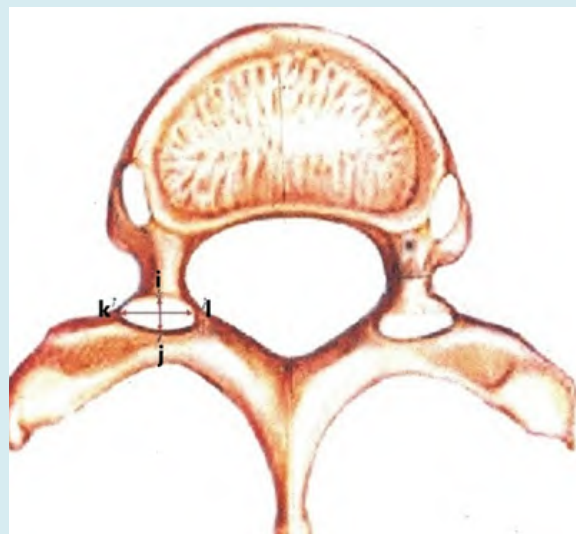

Figure 3: (For Chapter 9) Superior View of Vertebra Prominens Showing The Dimensions Of Inferior Articular facets.

Transverse Process

- **Foramen Transversarium Length (FTL):** It is the main antero posterior diameter measured as $MN = FTL$ [6].
- **Foramen Transversarium Width (FTW):** IT is the main transverse diameter breadth of FT measured as $mn = FTW$.
- **Foramen Transversarium Depth (FTD):** It is the maximum superoinferior diameter of foramen transversarium measured as $OP = FTD$.

Vertebral Foramen

- **Foramen Diameter Anteroposterior (FDAP):** It is the anteroposterior length of the vertebral canal from the center of superior margin of the body to the beginning of spine measured as $ab = FDAP$ [32-36].
- **Foramen Diameter Transverse (FDT):** It is the greatest

transverse diameter of vertebral canal measured as $cd = FDT$.

Spine

- **Spine Length (SL):** It is maximum anteroposterior diameter from the centre of superior margin of junction of two lamina upto Posterior most end of the spine measured as $UV = SL$ [37].
- **Spine Width Maximum (SW):** It is the maximum width of the spine from the centre of superior margin of junction of two lamina upto both the posterior ends of bifid spine measured as $XY = SW$ (maximum).
- **Spine Width Minimum (sw):** It is the minimum width of the spine from the centre of superior margin of junction of two lamina upto both the posterior ends of bifid spine measured as $xy = sw$ (minimum) Figure 4.

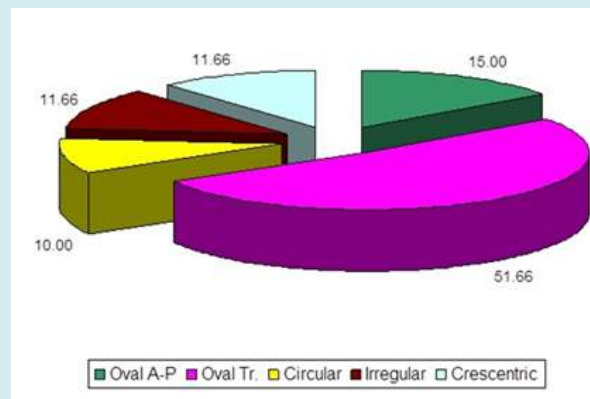


Figure 4: (For Chapter 9) Showing the Incidence of Types of Shapes of Articular Facets of Vertebra Prominens.

Summary

This study utilized dry bone specimens to measure vertebra Prominens's key parameters, including body

dimensions, pedicle, laminae, spinous process, and the diameters of the foramen transversarium and vertebral foramen. Standardized techniques ensured accuracy and consistency in data collection.

Chapter 10: Discussion: Evaluation of Measurements and Clinical Implications

The vertebral body of vertebra prominens was analyzed for various parameters including length, width, and height. Results showed some discrepancies when compared to previous studies, which could be attributed to racial, environmental, or anatomical differences. In terms of pedicles, superior, and inferior articular facets, no significant differences were observed between right and left sides, though the parameters were slightly different from earlier studies. Vertebral body measurements (VBL, VBSW, VBIW) were largely in line with previous research, with some variations attributed to racial or geographical factors. The vertebral body dimensions provide crucial anthropometric references for biomechanical modelling and surgical planning, especially for spinal fusion and anterior cervical discectomy procedures [29,36,38-40].

Pedicle dimensions (PL, PH, PW) showed slight asymmetry, though not statistically significant, indicating consistency across populations. Pedicle measurements are vital for understanding spinal canal narrowing in conditions like achondroplasia and for detecting intraspinal tumors [28,36].

Vertebra prominens (C7) laminae play an important role in the maintenance of cervical spine stability [36,41]. The dimensions of the laminae have not been extensively studied previously. The lamina dimensions (LL,LW,LH) supports the results given by Bazaldua et al. [42].

Cervical laminoplasty is a surgical procedure frequently used for the treatment of cervical spondylotic myelopathy [43], resection of spinal medulla tumours and ossified posterior longitudinal ligament [44].

Articular facets showed variation in length and width across different studies but were generally consistent with the population studied. Superior and inferior articular facets revealed racial differences that were statistically insignificant. Articular facet dimensions are critical for diagnosing and managing disc degeneration and potential facet joint asymmetry, which could predispose patients to disc herniation and spinal instability [36-39].

Foramen transversarium measurements were comparable with findings of earlier workers and vertebra Prominens showed highest frequency of type 4 of FT on right side and type 3 on left side [25]. None of the earlier authors have compared the parameters of both the sides in the available

accessible literature. Since vertebral vessels are a factor in formation of FT so it can be assumed that variations of FT can be useful for estimating changes of vessels and accompanying nerve structure. Normally FT of seventh cervical vertebra is big as it is occupied only by vertebral vein. A higher frequency of occurrence of accessory FT was also observed on left side. No double or triple FT was found [6].

The vertebral canal measurements were comparable with earlier work and important to know as C7 has several important clinical implications like cervical myelopathy, which occurs when the spinal cord is compressed at C7 or spinal stenosis, where the canal narrows due to degenerative changes or congenital factors. When these happen, the patient usually presents with neck pain, weakness, numbness, imbalance or tingling in the arms. A canal diameter of less than 10 mm is particularly concerning for stenosis. The C7 nerve root when exits through the intervertebral foramen near the C7 vertebra may be compressed due to herniated disc or foraminal stenosis and may cause C7 radiculopathy, which manifests as pain radiating down the triceps to the middle finger, along with weakness in wrist extension. Trauma to C7 is also clinically significant as high-impact injuries like car accidents or whiplash, can result in fractures that potentially compromise the vertebral canal, leading to spinal cord injury or neurological deficits or even paralysis. A specific type of injury, called a Clay-Shoveler's fracture may also involve the spinous process of C7 causing pain and reduced neck mobility [32,36,45].

Spine length and width showed limited comparative data from previous literature, highlighting a need for further anatomical studies. Spine measurements, including length and width, are important in evaluating trauma such as fractures and in the context of stabilizing procedures like the use of Halifax clamps for spine stabilization. Relationship between alignment of upper and lower cervical vertebral spine should be taken into consideration while performing cervical fusion [30,36,46,47].

The subject of cervical rib is one which concerns the general practitioners, because the patient consults when the symptoms appear. Adson presented that scalenus anticus muscle and width of its attachment were the principle factors in causing the symptoms with the cervical rib [48]. Clinically, C7 is important in diagnosing spinal conditions such as cervical spondylosis, disc herniation, and traumatic

injuries. Its structural prominence can also be associated with postural abnormalities, including kyphosis or forward head posture, which can lead to chronic neck pain and related conditions. Understanding the phylogeny of C7 provides insight into why this vertebra is particularly prone to stress and degenerative changes, as the evolution toward bipedalism increased the mechanical load on the cervical spine, especially at this prominent vertebra [49,50].

These anatomical details assist clinicians in diagnostic processes, treatment planning, and surgical interventions for

cervical spine injuries and pathologies.

Summary

The analysis revealed significant variability in the morphometric features of C7, highlighting its anatomical and clinical relevance. These variations are critical for planning surgical interventions, understanding neurovascular compression syndromes, and enhancing diagnostic precision in cervical spine imaging. The findings provide valuable insights for anatomists, clinicians, and surgeons.

Chapter 11: Advanced Imaging Techniques in Evaluating Vertebra Prominence (C7): The Role of MRI and CT Scans in Clinical Perspective

The vertebra prominens with its distinct and palpable spinous process serves as a transitional vertebra between the cervical and thoracic regions, contributing to the overall stability and mobility of the neck. Given its crucial anatomical position and functional role, accurate assessment of the C7 vertebra is essential, especially when evaluating spinal alignment, movement, and potential pathologies. Advanced imaging techniques, particularly Magnetic Resonance Imaging (MRI) and Computed Tomography (CT), are invaluable tools in the diagnosis and management of conditions affecting the vertebra prominens [51,52].

MRI provides high-resolution, multiplanar images that allows for detailed visualization of both the bony and soft tissue structures. MRI is instrumental in evaluating the soft tissue attachments at the C7 vertebra, such as muscles and ligaments. Thus, it is the imaging modality of choice for assessing the neural structures, and diagnosing conditions that involve compression of the spinal cord or nerve roots, which are commonly observed in cases of C7-related spinal stenosis. Furthermore, pathological conditions like disc herniations, infections, inflammation or neoplasms affecting the vertebra prominens can be detected early with MRI. MRI's ability to capture dynamic changes in the spinal structures and the absence of ionizing radiation makes it ideal for longitudinal follow-ups in patients with chronic cervical spine issues, thus aiding in effective monitoring of disease progression or treatment outcomes [52,53].

The high-resolution, cross-sectional images generated by CT scans are essential for providing detailed images of the bony anatomy of the C7 vertebra. It allows for precise measurement of the vertebra's dimensions, including the pedicles, transverse processes, and foramen transversarium,

which are critical for understanding the biomechanics and function of the C7 vertebra. CT is the gold standard for detecting fractures or structural deformities in the vertebra prominens. Additionally, CT scans play a significant role in identifying bony abnormalities such as osteophytes, facet joint arthropathy, and other degenerative changes that may contribute to spinal stenosis or nerve root compression at the C7 level. These findings are crucial in determining the need for surgical intervention, such as spinal decompression or fusion, guided biopsies, nerve blocks and in planning the appropriate approach for treatment [52,54].

While MRI and CT scans each offer distinct advantages, when used together, these imaging techniques allow radiologists to provide a thorough assessment of the C7 vertebra, facilitating accurate diagnoses and aiding in the development of a tailored treatment plan. This combined approach is particularly useful in cases of complex spinal pathologies, where both soft tissue and bony abnormalities need to be addressed [52].

Summary

The Vertebra Prominens's critical role in cervical spine function makes its accurate assessment essential in both normal and pathological conditions. MRI and CT scans provide complementary insights, enabling radiologists to detect, diagnose, and manage a wide range of conditions affecting the vertebra prominens. These imaging techniques not only enhance our understanding of the C7 vertebra's role in spinal health but also significantly improve the clinical management and treatment outcomes for patients with cervical spine pathologies.

Chapter 12: Conclusion: Summary of Findings and Directions for Future Research

This chapter highlights the anatomical significance and developmental aspects of vertebral prominence, emphasizing its importance in anatomical education and clinical practice. The morphological and morphometric analysis of the vertebra prominens, including parameters of vertebral body, pedicle, laminae, articular facets, foramen transversarium, vertebral canal and spine provide valuable insights into anatomical variations influenced by racial, environmental, and genetic factors. These measurements are crucial for clinical applications, particularly in surgical procedures, spinal injury assessments, and understanding conditions such as spinal canal narrowing and disc degeneration. The data serves as an important reference for anatomical, biomechanical, and anthropometric studies, contributing to improved patient outcomes in spinal disorders and surgeries. The detailed examination of seventh cervical vertebra, with its unique anatomical features, its development, and variations, along with insights from historical and contemporary research, underscores the importance of this vertebra in

clinical practice. Continued research and clinical observation will further elucidate the implications of these variations and improve the management of cervical spine disorders. Additionally, the clinical relevance of the vertebra prominens (C7) is closely tied to its evolutionary development. Phylogenetically, C7 evolved to support increased head and neck mobility in bipedal species, which is crucial for tasks like balance, sensory orientation, and locomotion. In humans, the prominence of C7 plays a significant role as a landmark in clinical practice. It is easily palpable and is often used as a reference point for counting vertebrae during physical examinations or medical imaging. The integration of MRI and CT scans into the evaluation of vertebra prominens significantly enhances the diagnostic accuracy and clinical decision-making capabilities of radiologists. These advanced imaging techniques provide a deeper understanding of the anatomical and pathological nuances, ensuring better patient care and outcomes.

Acknowledgement

I extend my deepest gratitude to those who have been instrumental in the journey of bringing this book to fruition. First and foremost, I dedicate this work to my beloved mother, Dr. Mrs. Indu Prabha Lalit, whose unwavering love, guidance, and strength continue to inspire me. Her values and wisdom have shaped the person I am today, and though she is not physically present, her presence is felt in every step of my life. I would also like to pay tribute to my late father, Mr. Satish Kumar Lalit, whose principles, perseverance, and unconditional love have been a guiding light in my life. His unwavering belief in my abilities and constant encouragement have been the cornerstone of my achievements. Though he is no longer with us, his memory continues to inspire me, and this work reflects the values he instilled in me. To my mother-in-law, Mrs. Shakuntala Piplani, I express my heartfelt gratitude for her kindness, wisdom, and unwavering support. Her understanding and encouragement have been a source of strength, enabling me to dedicate time and effort to this work. Her presence in my life has been a blessing, and I am deeply thankful for her love and guidance. To my husband, Dr. Sanjay Piplani, your endless support, patience, and encouragement have been my pillars throughout this endeavour. Your love and belief in my dreams have been my driving force. To my children, Niharika Piplani and Sana Piplani, your constant love and motivation has given me the strength to overcome challenges. You both are my pride, and your support has been invaluable in completing this work. A special note of appreciation goes to my co-authors, Dr. Sanjay Piplani and Niharika Piplani, for their collaboration and commitment to excellence in this work. Your insights and efforts have been indispensable. Lastly, I am immensely thankful to my Respected Teachers, Students, Colleagues, and the academic community who have inspired and supported me in various capacities.


With heartfelt gratitude,
Dr. Monika Lalit

References

- Bergman RA, Afifi AK, Miyachi R (2007) Illustrated Encyclopedia of Human anatomic variation: Opus V: skeletal system: vertebral column – cervical vertebrae. Anatomy Atlases.
- Das S, Suri R, Kapur V (2005) A Duplicated Spinous process of the C7 vertebra. *Folia Morphologica* 64(2): 115-117.
- Delbarre F, Ramadier JO, Laprusle J, Coste F, Paolaggi JB (1963) Apophysomegaly of the 7th cervical vertebra with acroparesthalgia and amyotrophy of the hand. *Rev Rhum Mal Osteoartic* 30: 125-127.
- Mann CV, Russell RCG (1992) The Spine, Vertebral column and spinal cord. In: Bailey, et al. 21st (Edn.), ELBS with Chapman and Hall, London, pp: 493-500.
- Maresova J (1950) X-ray Radiation of the 7th Cervical Vertebra in the Treatment of Psoriasis. *Cesk Dermatol* 25(7-8): 297-299.
- Taitz C, Nathan H, Arensburg B (1978) Anatomical observations of the foramina transversarium. *J Neurol Neurosurg Psychiatry* 41(2): 170-176.
- Nathan H (1962) Osteophytes of the vertebral column-An anatomical study of their development according to age, race and sex with considerations as to their etiology and significance. *J Bone and Joint Surg* 44(2): 243-268.
- Gupta M, Bharihoke V, Bhargava SK, Agarwal N (1998) Size of the vertebral canal -A correlative study of measurements in radiographs and dried bones. *J Anat Soc India* 47: 1-6.
- Schellinger PD, Schwab S, KriegerD, Fiebach JB, Steiner T, et al. (2001) Masking of vertebral artery dissection by severe trauma to the cervical spine. *Spine* 26(3): 314-319.
- William M, Newell RLM, Collin P (2016) The back: cervical vertebrae. In: Standring S, et al. (Eds.), *Gray's Anatomy*. 41st (Edn.), Elsevier Churchill Livingstone, Edinburg, London, pp: 724-727.
- Smith JL, Herring SW (2010) Evolution of vertebral structures and function. *J Vertebr Morphol* 45(3): 301-318.
- Bryce TH (1915) Osteology the Skeleton-Vertebral Calumn. In: Schaffer EA, et al. (Eds.), *Quains elements of anatomy*. 11th (Edn.), Longmans Green and Co, London, pp: 5-34.
- Spalteholz W (2019) Bones of the spine. In: *Hand atlas of human anatomy*. 7th(Edn.), Lippincott Company, Philadelphia, London, pp: 72-85.
- Chaurasia BD (1990) Head & neck and brain-cervical vertebrae. In: *Human anatomy regional and applied*. CBS Publishers and Distributors 204.
- Pan N (2001) Fusion of cervical vertebrae-Anatomical notes. 66: 426-429.
- Cooper DF (1980) Bone erosion of the cervical vertebrae secondary to tortuosity of the vertebral artery-case report. *J Neurosurg* 53(1): 106-108.
- Anderson RE, Shealy CN (1970) Cervical pedicle erosion

- and rootlet compression caused by tortuous vertebral artery. *Radiology* 96(3): 537-538.
18. Inderbir Singh (2002) Cervical vertebrae. In: *Textbook of human Osteology*. 2nd(Edn.), Medical Publishers LTD, New Delhi, pp: 98-103.
 19. Francis CC (1955) Variations in the articular facets of the cervical vertebrae. *Anat Rec* 122(4): 589-602.
 20. Palma A, Carini F (1990) Variation of the transverse apophysis of the 7th cervical vertebra: anatomoradiological study of an isolated population. *Arch Ital Anat Embriol* 95(1): 11-16.
 21. Borejko J (1954) Fracture in the spinous process of the 7th cervical vertebra. *Pol Przegl Radiol* 18(1): 1-6.
 22. Nikitin MN (1975) Dislocation of the 7th Cervical vertebra. *Ortop Travmatol Protez* 4: 44-46.
 23. Anderson RJ (1883) Observations on the diameter of human vertebrae in different regions. *J Anat and Physiol* 17(3): 341-344.
 24. Cyriax EF (1920) On current absolute and relative measurements of human vertebrae. *J Anat* 54: 305-308.
 25. Willis TA (1929) An analysis of vertebral anomalies. *Am J Surgery* 6(2): 163-168.
 26. Cave AJE (1930) Bilateral cervical rib - The earliest English example of bilateral cervical rib. *British J Surg* 29(113): 47-51.
 27. Wood JF (1938) The cervical vertebrae of the Australian native. *J Anat* 72: 411-415.
 28. Hinck VC, Hopkins CE, Savara BS (1962) Sagittal diameter of the cervical spinal canal in children. *Radiology* 97:108.
 29. Gilad I, Nissan M (1985) Sagittal evaluation of elemental geometrical dimensions of human vertebrae. *J Anat* 143: 115-120.
 30. Fujiwara K, Yonenobu K, Ebara S, Yamashita K, Ono K (1989) The prognosis of surgery for cervical compression myelopathy. *J Bone and Joint Surg* 71(3): 393-398.
 31. Hyppa SE, Laasonen EM, Halonen V (1974) Erosion of cervical vertebrae caused by elongated and tortuous vertebral arteries. *Neuroradiology* 7(1): 49-51.
 32. Francis CC (1955) Dimensions of cervical vertebrae. *Anat Rec* 122: 603-609.
 33. Scoles PV, Linton AE, Latimer B, Levy ME, Digiovanni BF (1988) Vertebral body and posterior element morphology: The normal spine in middle life. *Spine* 13(1): 1082-1086.
 34. Madawi AA, Solanki G, Casey ATH, Crockard HA (1997) Variations of the groove in the axis vertebra for the vertebral artery - Implications for instrumentation. *J Bone and Joint Surgery* 79(5): 820-823.
 35. Xu R, Nadaud MC, Ebraheim NA, Yeasting RA (1995) Morphology of the second cervical vertebra and the posterior projection of the C2 pedicle axis. *Spine* 20(3): 259-263.
 36. Lalit M, Piplani S, Kullar JS, Mahajan A (2019) A Morphometric study of body, lamina, spinous process and vertebral foramen of vertebra prominens (C7) in north indian population: A clinico-Anatomical approach. *Int J Anat Res* 7(4.2): 7105-7112.
 37. Cunningham DJ (1886) The neural spines of the cervical vertebrae as a race character. *J Anat and Physiol* 20(4):637-640.
 38. Pal GP, Routal RV, Saggi SK (2001) The orientation of the articular facets of the zygapophyseal joints at the cervical and upper thoracic region. *J Anat* 198(4): 431-441.
 39. Sahoo PK, Singh P, Bhatoe HS (2004) Stabilization for sub axial cervical spine injury. *IJNT* 1(1): 43-47.
 40. Collins CU (1930) Cervical ribs. *Am J Surg* 14(2):449-451.
 41. Pal GP, Routal RV (1986) A study of weight transmission through the cervical and upper thoracic regions of the vertebral column in man. *J Anat* 148: 245-261.
 42. Bazaldúa CJJ, Gonzalez LA, Gomez SA, Villarreal SEE, Velazquez GSE, et al. (2011) Morphometric study of cervical vertebrae C3-C7 in a population from northeastern Mexico. *Int J Morphol* 29(2): 325-330.
 43. Hosono N, Sakaura H, Mukai Y, Fuji R, Yoshikawa H (2006) C3-6 laminoplasty takes over C3-7 laminoplasty with significantly lower incidence of axial neck pain. *Eur Spine J* 15: 1375-1379.
 44. Wang JM, Roh KJ, Kim DJ, Kim DW (1998) A new method of stabilising the elevated laminae in open-door laminoplasty using an anchor system. *J Bone Joint Surg* 80: 1005-1008.
 45. Batzdorff U, Batzdorff A (1988) Analysis of cervical spine curvature in patients with cervical spondylosis. *Neurosurgery* 22(5): 827-836.
 46. Bertram C, Madert J, Eggers C (2002) Eosinophilic

- granuloma of the cervical spine. *Spine* 27(13): 1408-1413.
47. Sherekar SK, Yadav YR, Basoor AS, Baghel A, Adam N (2006) Clinical implications of alignment of upper and lower cervical spine. *Neurol India* 54(3): 246-247.
 48. Buchholtz EA, Stepien CC (2009) Anatomical transformation in the vertebral column: Evolutionary perspectives on vertebral regionalization and specialization. *Integr Comp Biol* 49(2): 590-600.
 49. Bogduk N (2014) Clinical anatomy of the cervical spine. *Pain Physician* 17(5): 529-535.
 50. Flannigan BD (1987) Cervical Epidural Venous Plexus and Acute Herniated Disks. *American Journal of Neuroradiology* 8(1): 29-34.
 51. Patel V, Bartels RHMA (2022) Imaging of the Cervical Spine: CT and MRI in Evaluating Structural and Neurological Pathologies. *J Radiological Sciences* 15(4): 273-285.
 52. Katzberg RW, Linsenmeyer TA, Benedetti PF, Drake CM, Ivanovic M, et al. (1999) Acute cervical spine injuries: Prospective MR imaging assessment at a level 1 trauma center. *Radiology* 213(1): 203-212.
 53. Hoffman M (2021) CT Scan Applications in Assessing Cervical Spine Trauma: A Focus on C7 Vertebra. *Radiology and Imaging Sci* 12(3): 112-119.
 54. Smith J, Brown K (2020) Advanced Imaging in Spinal Pathologies: The Role of MRI and CT. *Inter J Clinical Imaging* 9(1): 34-42.





MEDWIN PUBLISHERS
Committed to Create Value for Researchers

OUR DEPARTMENTS



Contact details:

Contact link: <https://www.medwinpublishers.com/contact-us.php>

Or,

Email: info@medwinpublishers.org

Tel no: +1-248-247-6042

FAX no: +1-248-742-3423

Privacy policy: <https://www.medwinpublishers.com/privacy.php>

Copyright: Copyrighted with creative common licence

<https://creativecommons.org/licenses/by/4.0/>